

Issels Immuno-Oncology

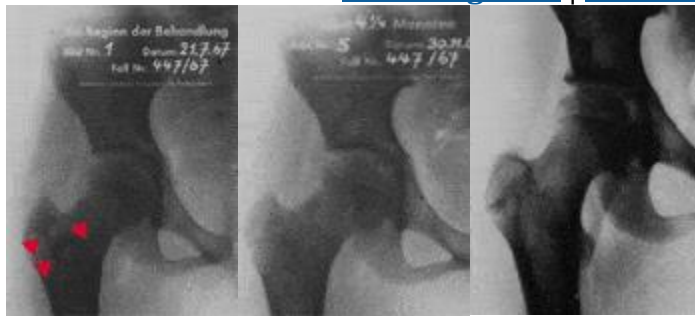
Primary OsteoSarcoma of Right Thigh

Complete Long-Term Remission of a Primary OsteoSarcoma of Right Thigh Through the Issels Treatment Without Standard Treatment

Patient G.P. Born 1957, file No. 447/67

28 years cancer free without any recurrence. Patient got married and became a mother of 4 and emigrated to Australia.

TREATMENT HISTORY [First Diagnosis](#) | [Issels Treatment](#)



First Diagnosis

June 1967

Histology, Prof. Glogengiesser, Munich: Reticular Sarcoma. **Amputation of leg recommended. Father refused all conventional therapy.**

Issels Treatment

July 1967

Admission to Dr. Issels' hospital with untreated primary reticular Sarcoma.

Radiological findings on admission: On the right trochanter within a triangular field of 4:2:1 several circular foci of decalcification.

July to September 1967

Eight weeks of Issels Treatment. Partial remission.

November 1967

Complete Remission.

Follow-up until 1995

Issels Immuno-Oncology

Winter 1969

The patient won a skiing competition.

Revealed 28 years cancer free without any recurrence. Patient got married and became a mother of 4 and emigrated to Australia.

DISCLAIMER: No claim is made that patients with similar diagnosis and/or treatment(s) will respond to the same extent as the patients shown. All testimonials have been provided voluntarily to share a patient's experience with the Issels Treatment and their state of health at the time. Some patients may have passed away due to age or disease. None of these patients received compensation or are related to the Issels Treatment Centers.